Curvature of the SPINE

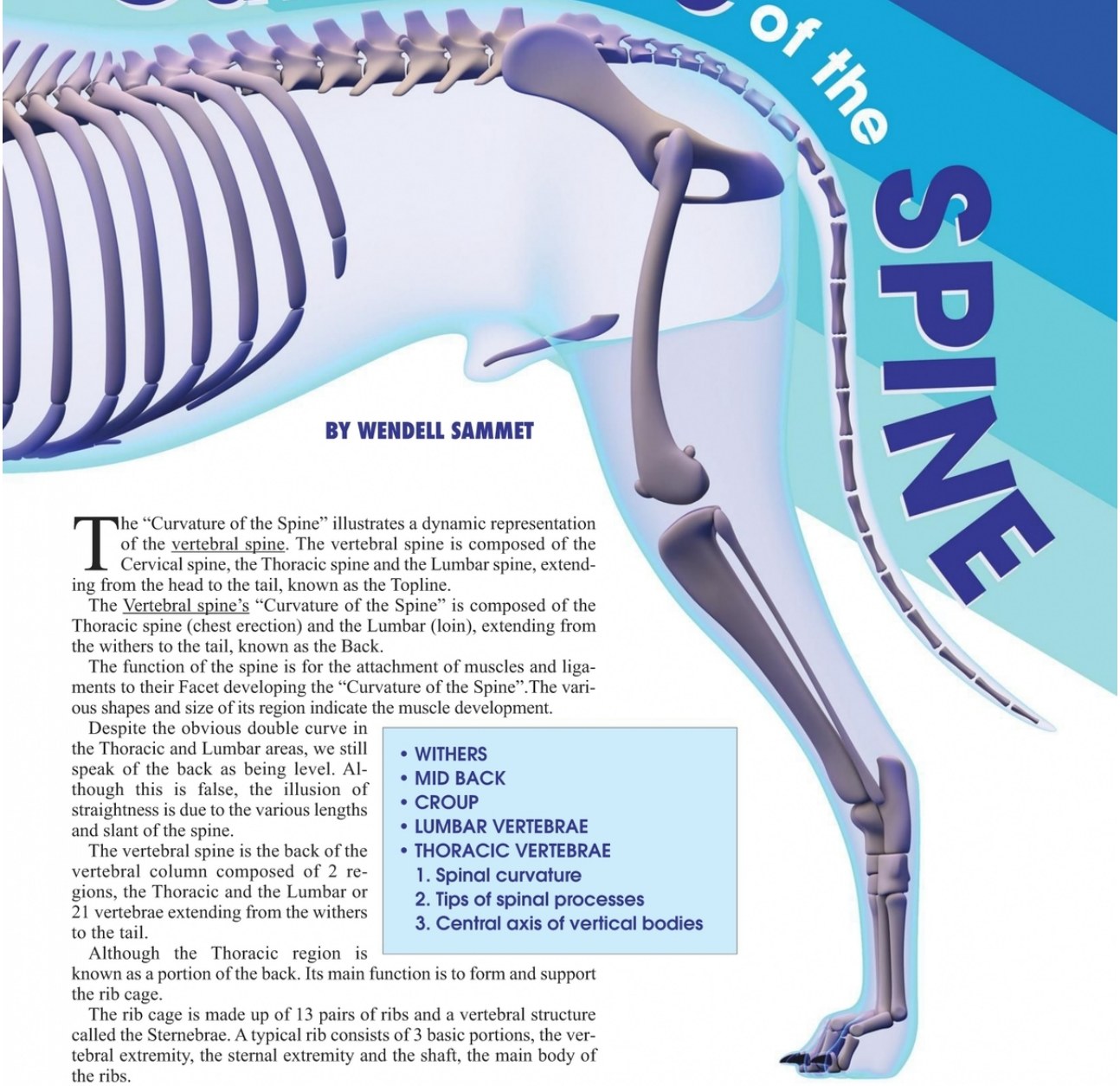

BY WENDELL SAMMET

The "Curvature of the Spine" illustrates a dynamic representation of the vertebral spine. The vertebral spine is composed of the Cervical spine, the Thoracic spine and the Lumbar spine, extending from the head to the tail, known as the Topline.

The Vertebral spine's "Curvature of the Spine" is composed of the Thoracic spine (chest erection) and the Lumbar (loin), extending from the withers to the tail, known as the Back.

The function of the spine is for the attachment of muscles and ligaments to their Facet developing the "Curvature of the Spine".The various shapes and size of its region indicate the muscle development.

Despite the obvious double curve in the Thoracic and Lumbar areas, we still speak of the back as being level. Although this is false, the illusion of straightness is due to the various lengths and slant of the spine.

- WITHERS
- MID BACK
- CROUP
- LUMBAR VERTEBRAE
- THORACIC VERTEBRAE
  1. Spinal curvature
  2. Tips of spinal processes
  3. Central axis of vertical bodies

The vertebral spine is the back of the vertebral column composed of 2 regions, the Thoracic and the Lumbar or 21 vertebrae extending from the withers to the tail.

Although the Thoracic region is known as a portion of the back. Its main function is to form and support the rib cage.

The rib cage is made up of 13 pairs of ribs and a vertebral structure called the Sternebrae. A typical rib consists of 3 basic portions, the vertebral extremity, the sternal extremity and the shaft, the main body of the ribs.

- VERTEBRAL EXTREMITY
- SHAFT (BODY)
- STERNAL EXTREMITY
- STERNEBRAE
- TUBERCLE
- NECK
- HEAD

The vertrabral extremity is the proximal portion of the rib, the head, neck and tubercle.

The head is round, hard and smooth, it articulates with the corresponding socket, a cup shape depression of the vertebrae.

The neck is just distal to the head and rib.

The Tubercle is a rounded articular area on the rib which articulates with the end of the transverse process. The Tubercle articulates with the corresponding end of the transverse process or the vertebrae of the same number as the rib.

- XIPHOID PROCESS
- STERNEBRAE
- MANUBRIUM

The Sternal extremity is a continuation of the shaft formed by cartilage; opposed to the other two portions that are of bone. This is the portion that articulates with the first 9 ribs of the sternebrae, called the "True Ribs". The 9 thru 12 do not articulate with the sternum, but are usually attached to the other sternebrae by cartilage one way or another. The 13th is a floating rib.

The shaft of the rib is roughly oval in the cross-section with the Distal end somewhat enlarged. The anterior first 6 to 7 ribs are flattened, allowing a smooth surface for the scapular to move over. The remaining ribs are much more rounded in cross-section to the anterior ribs.

- SPINOUS PROCESS FACETS
- TRANSVERSE PROCESS FACETS
- FORAMEN
- BODY

There is a projection at the most anterior of the rib cagd called the Manubrium and a triangular shaped projection at the posterior called the Xiphoid process. Xiphoid is Greek for straight sword.

The function of the rib cage is to protect the Thoracic contents and house a bellow-like action necessary for breathing. The most important is the supporting structure for the form of the living assembly. It also determines the width and depth of the dogs chest.

Each region of the spine is composed of various lengths and slant of the spinous processes. Their facet is attached to muscle which develop through curves of the spine.

The "Curvature of the Spine" (Thoracic + Lumbar) starts at the withers of the Thoracic vertebrae, forming a concave curve of long slanting spinous processes facing forward towards the tail. They gradually reduce in size marking the tips of the last spinous processes of the Thoracic area, the 9th vertebrae. These 5 spinous processes are short, upright and level, called the mid-back. Their spinous processes change direction from backwards to forward, making the 7 lumbar with spinous processes facing forward at the 15th vertebrae of the spine. The 7 vertebrae are long, strong and massive allowing for strong muscle attachment, important for transmitting force from the rear assembly to the rest of the body.

TWO VERTEBRAE JOINED BY A INTERVERTEBRAL DISC

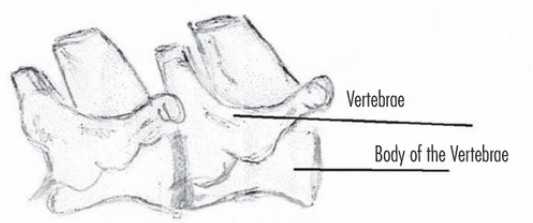

The lumbar spine is convex dorsally reversing the curve as it slopes upwards towards the pelvis, ending with a rise over the loin (croup).

The 7 lumbar vertebrae are longer and heavier than the Thoracic, extending from the Thoracic spine to the tail. The spinous processes and the transverse processes are massive, allowing for larger muscle attachment, important for posture and locomotion.

The function of the lumbar spine is to support the abdominal organs and pelvis. The main function is to transmit force from the rear assembly to the rest of the body.

The sacrum, 3 fused vertebrae, join the lumbar forming a strong anchor for the hind assembly. The fused transverse processes and the sacrum articulate by a cartiligous type joint, with the pelvis on both sides. This union allows a direct transfer of forces from the hind limbs of the vertebral column.

The 3 fused bones of the posterior portion of the pelvis forms a central fusion creating a deep, sturdy ball and socket joint called the acetabulum. The articulation of the acetabulum and the spherical head of the femur of the hind limbs, support the rear quarters and transmits force for propulsion to the rest of the dog.

THE ASSOCIATION OF THE INTERVERTEBRAL DISC WITH THE VERTEBRAE

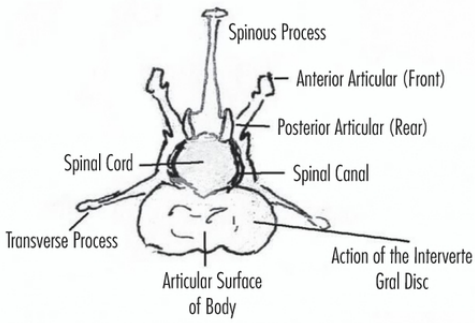

Vertebral Column

The vertebral column, the spinal column, the central axis of the spinal column and the curvature of the spine forms the Vertebral Column.

The vertebral column is composed of a series of irregular bones arranged in such a manner as to furnish a sturdy, flexible column, extending from the skull to the tail. The organiza-

tion of the vertebral column fulfills the functional requirements of the animal.

The vertebral column is composed of 5 anatomical regions, all of which have an individual function. The 7 cervical vertebrae form the neck region. Its first two vertebrae are the Atlas and the Axis. They are shaped different than the 5 remedial vertebrae, specialized to allow almost complete freedom of the head movement in all directions.

The 14 Thoracic vertebrae provide a base for the attachment of the ribs, forming the rib cage of 13 ribs.

The 7 lumbar vertebrae form the upper part of the loin area, and acts as a support for both the abdominal organs and pelvis.

The 3 fused vertebrae and the first 4 coccyx (tail) form the croup.

The sacral region, is the sacrum, and has a minimum amount of movement. The sacral region provides a firm attachment for the bones and muscles of the pelvis.

The coccyx (tail) vertebrae gradually reduce in size from sacral attachment to the tip. The basic function of the vertebral column is to support the anterior and posteriors to allow specific movement to the head and topline, to protect the spinal cord to the 4th lumbar, and to act as a flexible, slightly compressable rod, through which the propelling force generated by the hind limbs is transmitted to the rest of the body.

VERTEBRAL COLUMN

- CERVICAL VERTEBRA
- THORACIC VERTEBRA
- MID-BACK
- LUMBAR VERTEBRA
- SACRUM

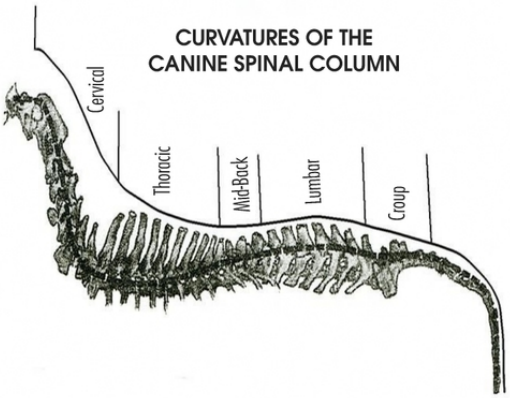

The Vertebrae

Each vertebrae is an individual in their structure, but they all have a body, an arch and processes. The body is a cylindrical mass of bone at the lower portion of the vertebrae. It presents a convex anterior, articulating surface which articulates with the succeeding vertebrae. Immediately dorsal to the body is an opening enclosed by a semi-circle of bone through which the spinal cord passes to the 4th lumbar vertebrae. It is called the "Vertebral Foramen."

Dorsal to the Foreman is a mid-line projection of bone which resembles a "spine", the spinous processes. The spine's function is for the attachment of muscles and ligaments to their facet or joint at the tip. The spine's length and slant vary from region to region; forming the curvature of the spine.

The arch is a semi-circle bridge of bone from side to side. The top of the arch is formed by bone. There are two anterior processes and two posterior processes for attachment that project from the borders or the arch.

The articulating vertebrae ordinarily articulates with adjacent verterbrae by three surfaces. The body of the vertebrae articulates with the bodies of the vertebrae in front and behind. The anterior articular process articulates with the anterior articular process of the succeeding vertebrae.

The articular surfaces of the vertebrae are so arranged as to limit extensive motion between any of the vertebrae.

Projecting laterally from each side of the vertebrae or the arch is another projection for muscle attachment called transversal process. The Atlas has a very thick, long transverse process called wings.

Each vertebrae articulates with the adjacent vertebrae separated by a pad called an "intervertebral disc". The disc consists of a rough, fibrous outer layer with a soft, jelly-like interior firmly attached by ligaments. This is a geodesic type of structure and allows for compressive, expansive, and rotary movement with maximum strength. This allows a restricted type of movement between the vertebral bodies and one addition has a hydrall effect, acting as a shock absorber. This is very important for the absorption of the force transmitted from the hind limbs.

References

- *Dog Anatomy*, Peter Goody
- *A Hobby or Profession*, Catherine Gardner
- *The Dog In Action*, McDowell Lyons
- *Canine Terminology*, Harold Spira
- *Functional Comparative Anatomy*, Logan Jurian & Walter Tyler